

RECOVERTENDO

For Soft Tissue Injuries

Effective and safe injections technique for management of upper limb tendinopathy and fasciopathy: Reconvertendo

Shoulder Joint

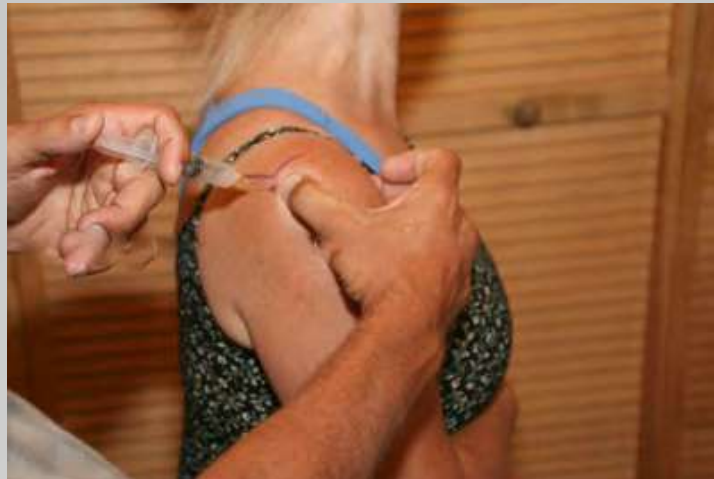

Figure 1. Intraarticular Reconvertendo injection of the shoulder.

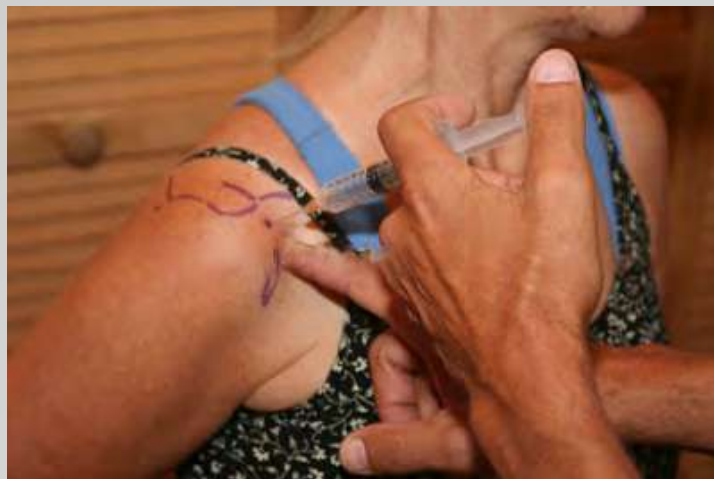

Figure 2. Reconvertendo injection of the supraspinatus tendon.

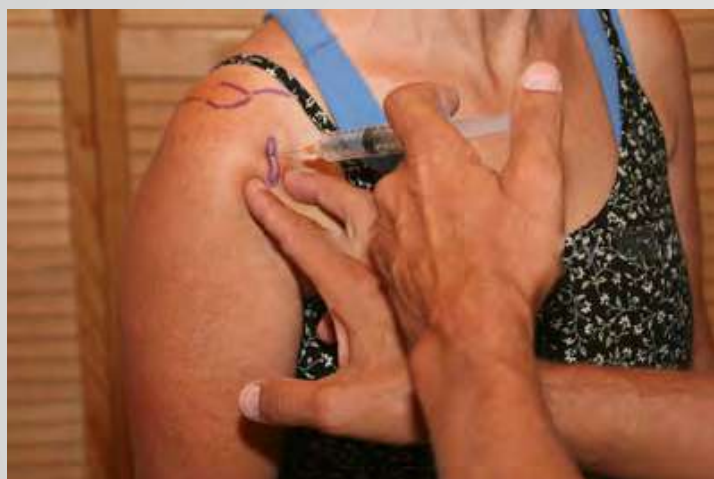

Figure 3. Reconvertendo injection into the subscapularis and pectoralis major tendons.



RECOVERTENDO

For Soft Tissue Injuries

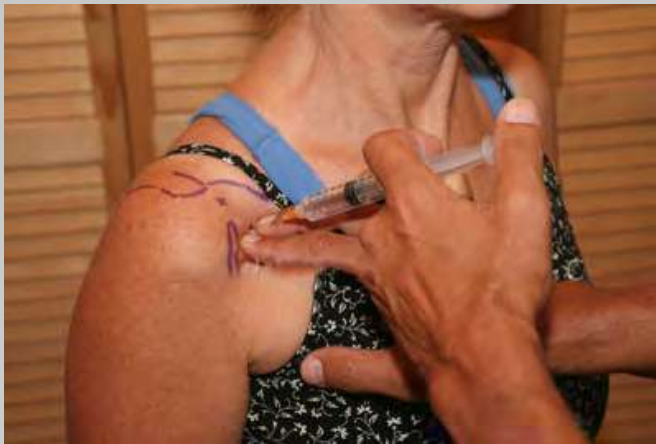

Figure 4. Recovertendo injection of the coracoid process. Many important structures attach here including: coraco-acromial, coraco-clavicular ligaments, and the long head of the biceps, coraco-brachialis and pectoralis minor tendons

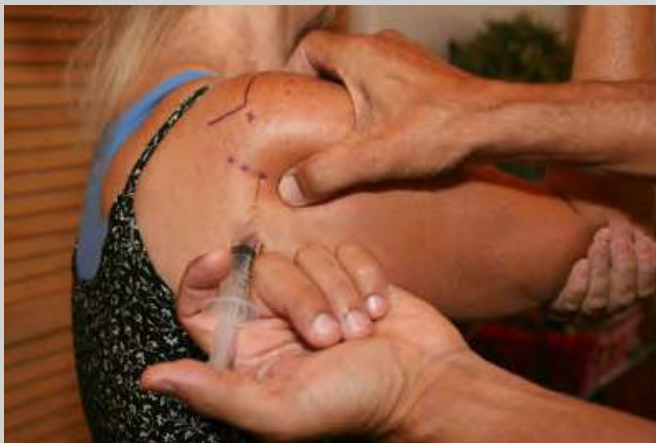

Figure 5. Recovertendo injection technique for the posterior shoulder. Injections of the posterior shoulder treat injuries to the infraspinatus and teres minor tendons.

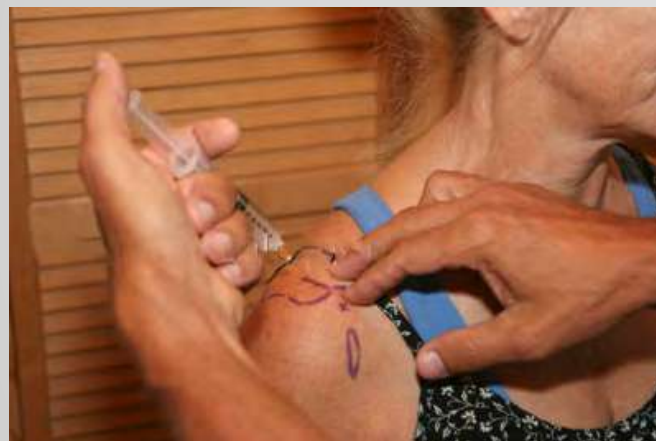

Figure 6. Recovertendo injection into and around the acromioclavicular joint.



RECOVERTENDO

For Soft Tissue Injuries

Elbow Joint

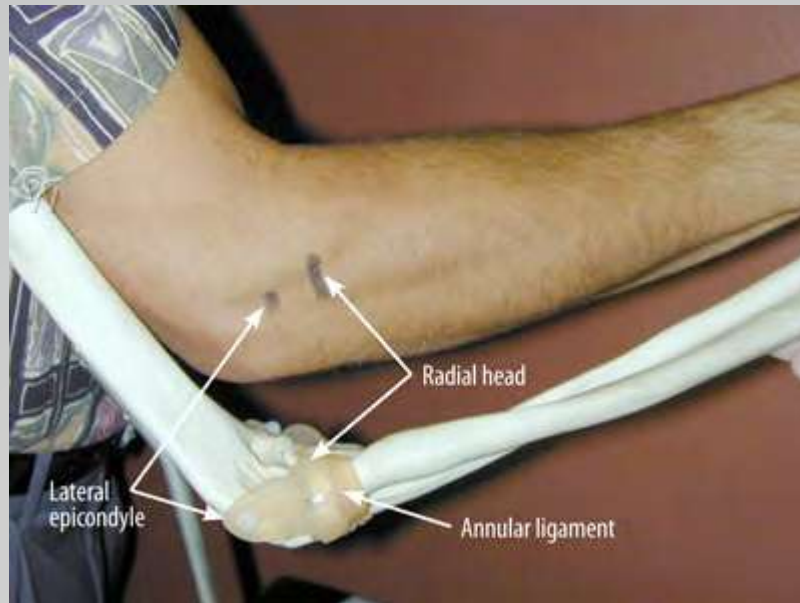


Figure 1a. Lateral view of elbow.

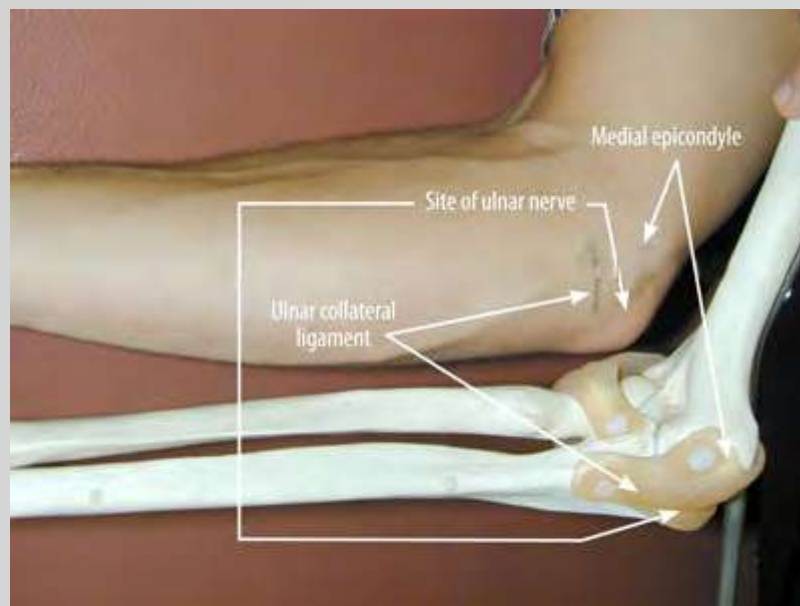


Figure 1b. Medial view of elbow.

RECOVERTENDO

For Soft Tissue Injuries



Figure 2. Injection to supra-condylar ridge.

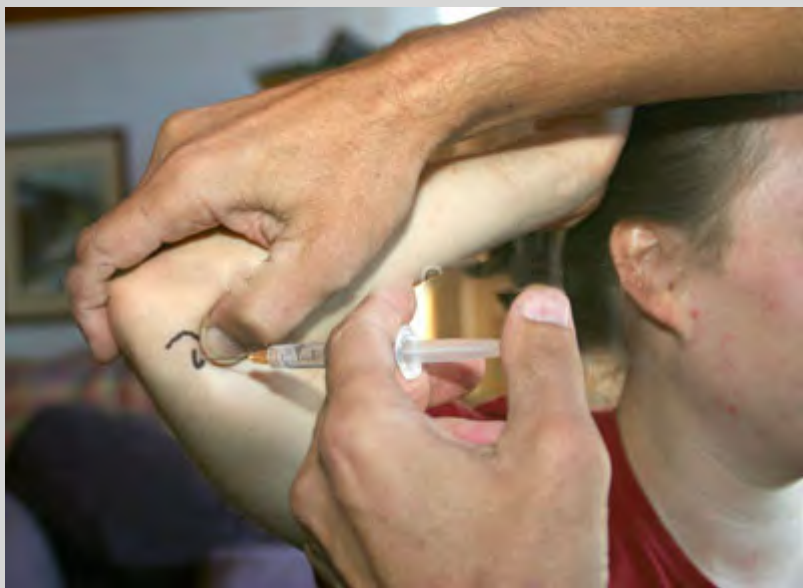

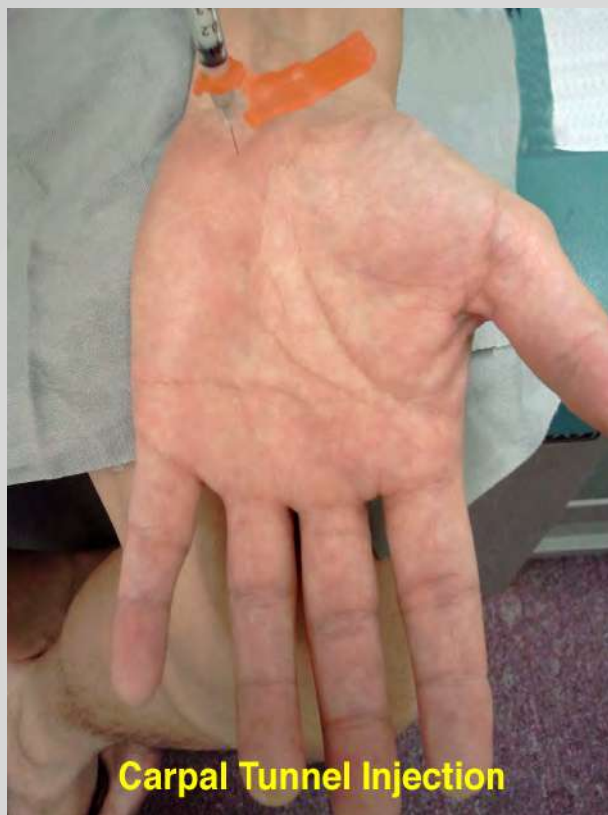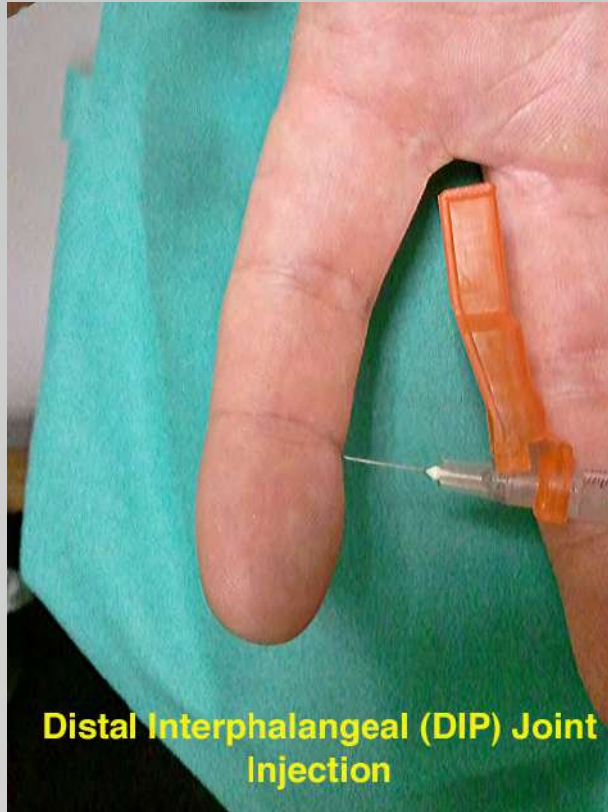
Figure 3. Injection of the medial epicondyle.



RECOVERTENDO

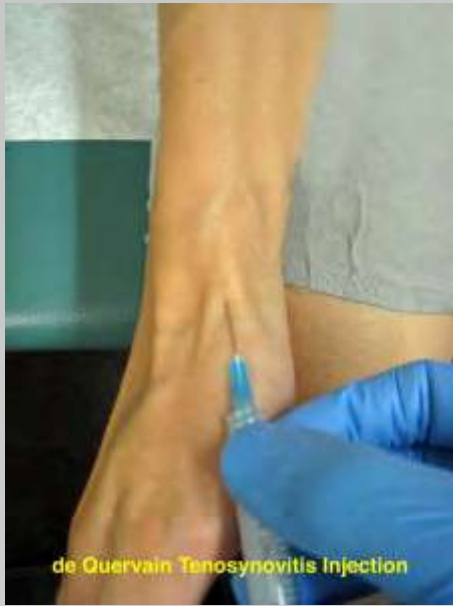For Soft Tissue Injuries

Hand Region



RECOVERTENDO

For Soft Tissue Injuries



Put needle between the abductor pollicis longus and extensor pollicis brevis tendon

